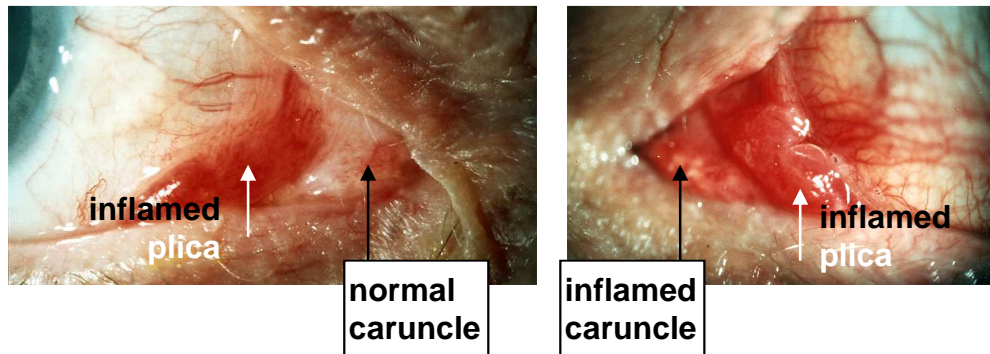


CARUNCLE AND PLICAL INFLAMMATION: HOW TO SCORE

Caruncle is normally yellowish pink and lies medial to plica, which is normally pink. Proptosis can prolapse caruncle forwards – this is not the same as inflamed



SCORING

prominent or prolapsed caruncle, but **not** inflamed
 plica prolapses through closed eyelids
 inflamed plica OR caruncle

score "no"
 score "yes"
 score "yes"

Yes = CAS positive