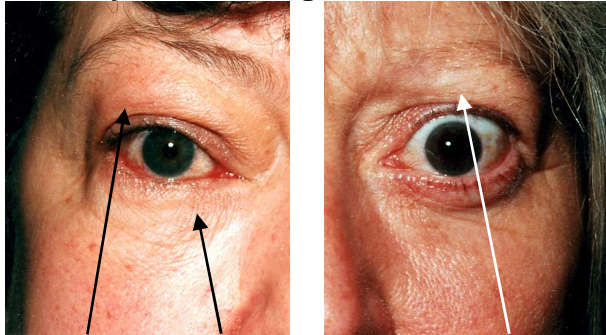


## EYELID SWELLING

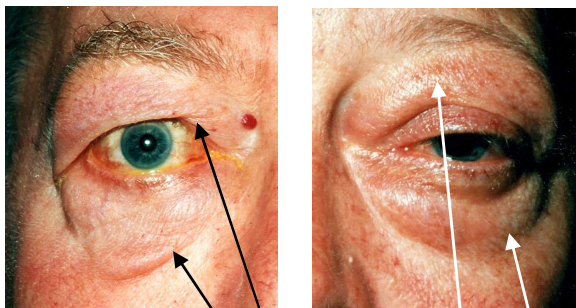
### HOW TO SCORE

#### MILD eyelid swelling



Patient may be aware of changed appearance, but appearance is similar to these photographs. CAS negative

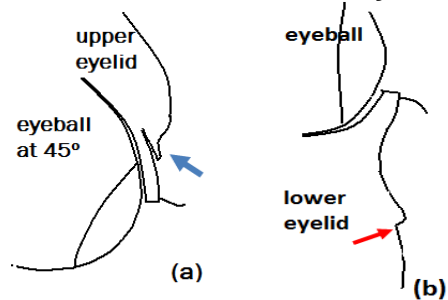
#### MODERATE eyelid swelling



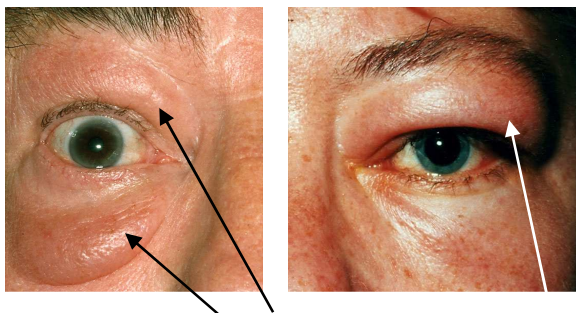
There is definite subcutaneous fluid (black arrows) or skin thickening (white arrows), (a) When patient to looks down at 45°, the skin fold in the central upper eyelid forms as angle (blue arrow).

(b) Swelling in lower eyelid, does not fold skin to form festoon (red arrow).

#### cross-sections of eyelids



#### SEVERE eyelid swelling



There is **tense** subcutaneous fluid (black arrows) or thickened skin (white arrows).

(a) When patient to looks down at 45°, the skin fold in the central upper eyelid remains rounded (blue arrow).

(b) Swelling in lower eyelid folds skin to form festoon (red arrow).

#### cross-sections of eyelids

